



## ORIGINAL ARTICLE

# ROLE OF COMPUTED TOMOGRAPHY IN DIAGNOSIS OF APPENDICITIS AND ITS COMPLICATIONS

Naglaa H Shebrya, Amr M Abdelsamad, Ayman A Elghandour\*

*Department of Radiodiagnosis, Faculty of Medicine - Ain Shams University, Egypt*

### \*Corresponding author:

**Ayman Abdalla Mohamed Elghandour**

*Department of Radiodiagnosis,  
Faculty of Medicine - Ain Shams  
University, Egypt*  
[dr.aymangh@gmail.com](mailto:dr.aymangh@gmail.com)

Submit Date 2019-03-17

Revise Date 2019-04-29

Accept Date 2019-05-28

## ABSTRACT

**Background:** Appendicitis and its complications are the most commonly acute abdominal pain that require surgical intervention. Patients may present with a wide variety of clinical manifestation. The clinical diagnosis is based primarily on the patient history, physical examinations and white blood cell count. Clinical diagnosis mostly straight forward in patients presenting with classic signs and symptoms, while diagnostic confusion and delay in treatment may occur in patients with atypical presentations. MSCT is a highly accurate means for establishing the diagnosis. **Objective:** The aim of the work is to describe the value and role of Multi-slice computed tomography in diagnosing appendicitis and its complications. **Methods:** This study retrospective study was conducted on patients with right lower quadrant or right flank pain. The study was conducted in Health Insurance hospitals Radiology department on Fifteen patients with right lower quadrant pain or right flank pain. **Results:** In the present study, we concentrate on continuity and thickness of the appendiceal wall. The normal appendix thickness is less than 1 mm. When appendix got inflamed, it usually appears thickened, asymmetric and enhancing with i.v. contrast from 1 to 3 mm thickness. **Conclusion:** MSCT is helpful for accurate and prompt diagnosis in suspected cases of appendicitis & its complications and conditions that mimic appendicitis. **Keywords:** Computed Tomography Diagnosis, Appendicitis , Complications

## INTRODUCTION

Appendicitis and its complications is the most common cause of abdominal pain that surgically managed, especially in the 10–30 year age group. Appendicitis was diagnosed by a clinical diagnosis without imaging, but recently computed tomography (CT) is considered the standard in diagnosing appendicitis [1].

For almost two decades CT being used widely in diagnosing appendicitis and its complications; studies demonstrated that CT have high specificity and sensitivity in

diagnosis. Use of intravenous iodinated contrast is the standard imaging practices. Positive oral (high-attenuation) contrast, and positive rectal contrast, also have been recommended [2].

CT scans showed uniformly high performance in diagnosing appendicitis with 95% specificity and 99% sensitivity , when using only oral, rectal, or intravenous (IV) contrast scanning techniques or combining oral, intravenous (IV) or rectal contrasts .Recently There is consequent increase in using preoperative diagnostic CT

scans in suspected cases of appendicitis and its complications to reduce the negative appendectomy rate [3].

MDCT can be used in evaluation of appendicitis preoperative effectively, providing high accuracy in detection of appendicitis, its complications and other findings that may cause right lower quadrant pain, helping the treating surgeon in taking decision and best management with these patients [4].

MDCT is recommended in cases with atypical confusing presentation especially in pediatric age group that present to Emergency department with abdominal pain and cannot be diagnosed correctly by clinical data and after doing sonography. MDCT scans have high accuracy in diagnosis appendicitis and alternative causes such as neoplasms and gastrointestinal abnormalities that may mimic appendicitis [5].

#### AIM OF THE WORK

The aim of the work is to describe the value and role of Multi-slice computed tomography in diagnosing appendicitis and its complications.

#### METHODS

**Type of study:** Retrospective study conducted on patients with right lower quadrant or right flank pain.

**Study Setting:** The study was conducted in Health Insurance hospitals Radiology department on cases referred from Emergency department.

**Study period:** 1 Year (During 2017 -2018)

**Study population:** Fifteen patients from patients with right lower quadrant pain or right flank pain.

#### Inclusion criteria

- Age group ( 16 years old to 60 years old )
- Patients that clinically suspected appendicitis and did abdominal CT scan
- Patients with right lower quadrant or right flank pain
- Patient with radiological evidence of acute appendicitis.

#### Exclusion criteria

- Pregnant women
- Persons over 60 years of age

- Persons with allergy to contrast medium
- Persons with acute and chronic respiratory and circulatory failure
- Persons with renal or hepatic failure

**Sampling Method:** This study was performed on simple random sample.

**Sample size:** Total sample: Fifteen patients from the Emergency department with right lower quadrant or right flank pain.

#### Ethical Considerations:

- Obtaining informed consent from the parents.
- Detailed explanation of the procedure to the patient (if old enough) and the patient's parents, detailed explanation of the complications as risk of development of contrast allergy, risk of Exposure to radiation, detailed explanation of management in case of development of complications.

The study was approved by the research ethical committee of Faculty of Medicine, Zagazig University. The work has been carried out in accordance with The Code of Ethics of the World Medical Association (Declaration of Helsinki) for studies involving humans.

**Study interventions:** Diagnostic agents.

#### Study procedure:

#### Patient preparation

For IV contrast: Fasting for 6 hours before IV administration.

Oral contrast prepared, 500–1000 mL gastrografin Given over a period of up to 45mins.

**Technique and CT imaging:** The study done from the dome of the diaphragm to the symphysis pubis using a 16 row Toshiba MDCT scanner with patient lying in the supine position.

**All patients will undergo routine abdominal CT imaging, including:** The axial cuts was reconstructed using a 5 mm thickness at 5 mm intervals. The reconstructed axial cuts reformatted in sagittal and coronal plane using a thickness of 3 mm at 5 mm intervals.

**Image analysis and results:** Coronal and axial images with separate series of images were transferred to a PACS workstation as a for interpretation,

### Statistical analysis

Data was collected, tabulated and was subjected to adequate statistical analysis including mean and standard deviations and were discussed to assess the additive value of Computed Tomography in diagnosis of acute appendicitis.

### RESULTS

The study included 15 patients complaining of right iliac fossa pain, only 4 patients (26.66 %) were with normal CT findings and patients (73.33 %) were with abnormal CT findings. **Table (1)**

Regarding sex distribution, 9 patients (60%) were males, while 6 patients (40%) were females **Table (2)**

The age of the patients ranged between 15-54 years with a mean age of 34 years with the range of 39 year. The most frequently involved age group was from 22-23 years in females and from 22-29 in males. **Figure (3)**

Among the 11 patients who have appendicitis or its complication:

- 5 patients (45.45 %) had Acute Appendicitis.
- 1 patient (9.09%) had chronic Appendicitis.
- 3 patients (27.27%) had Perforated Appendicis.
- 2 patients (18.18 %) had Appendicular abcess. **Figure (4)**

Illustrative cases:

#### Case NO. 1

**History:** A 29 year old male with right iliac fossa pain.

**Findings:** A CT scan axial , coronal and sagittal contiguous cuts were taken through the abdomen and pelvis with per-oral gastrografen, and after I.V. contrast injection showing markedly enhancing thickened wall

high level appendix that shows dilated fluid field appendix that contains appendicoliths.

**Diagnosis:** Acute appendicitis with appendicoliths

#### CASE NO. 2

**History:** A 22 year old male with right iliac fossa pain with fever.

**Findings:** A CT scan axial contiguous cuts were taken through the abdomen and pelvis with per-oral gastrografen, and after I.V. contrast injection showing large superficial well defined intraperitoneal fluid collection showing air foci surrounded with enhanced wall that extends from the left paracolic gutter , passing downwards and medially to the pelvis in close relation to the appendix measuring around 13x8.5x11 cm in its maximum TRxCCxAP dimensions. Generalized large and small bowel loops dilatation is noted with no definite obstruction lesions

**Diagnosis:** intraperitoneal abscess formation closely related to the appendix

#### Case NO. 3

**History:** A 38 year old male with right iliac fossa pain.

**Findings:** A CT scan axial, coronal and sagittal contiguous cuts were taken through the abdomen and pelvis with I.V. contrast injection showing appendicoliths that measures approximately 6 x 4 mm with dilated fluid filled appendix that shows significant enhancing interrupted thickened wall , There is surrounding misty mesentery with free fluid as well as midline collection that measures 15 x 10 mm.

**Diagnosis:** Perforated appendix with appendicoliths and surrounding inflammatory process.

3)Tables

**Table 1.** Distribution of patients according to CT findings.

|                                  | Patient numbers | Percentage % |
|----------------------------------|-----------------|--------------|
| Normal pelvi-Abdominal CT scan   | 4               | 26.66        |
| Abnormal pelvi-Abdominal CT scan | 11              | 73.33        |
| Total                            | 15              | 100          |

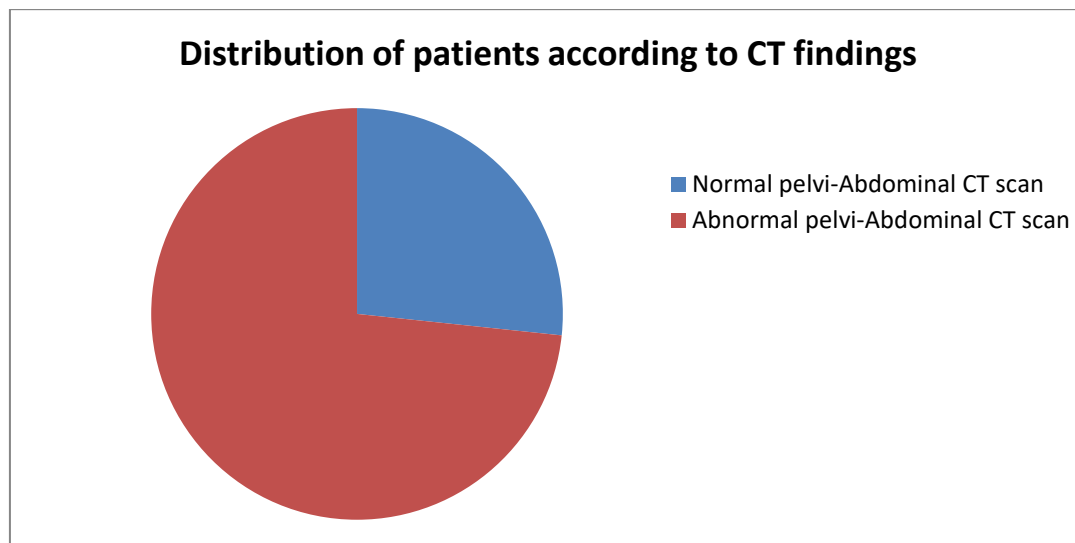
**Table 2.** Distribution of patients according to sex.

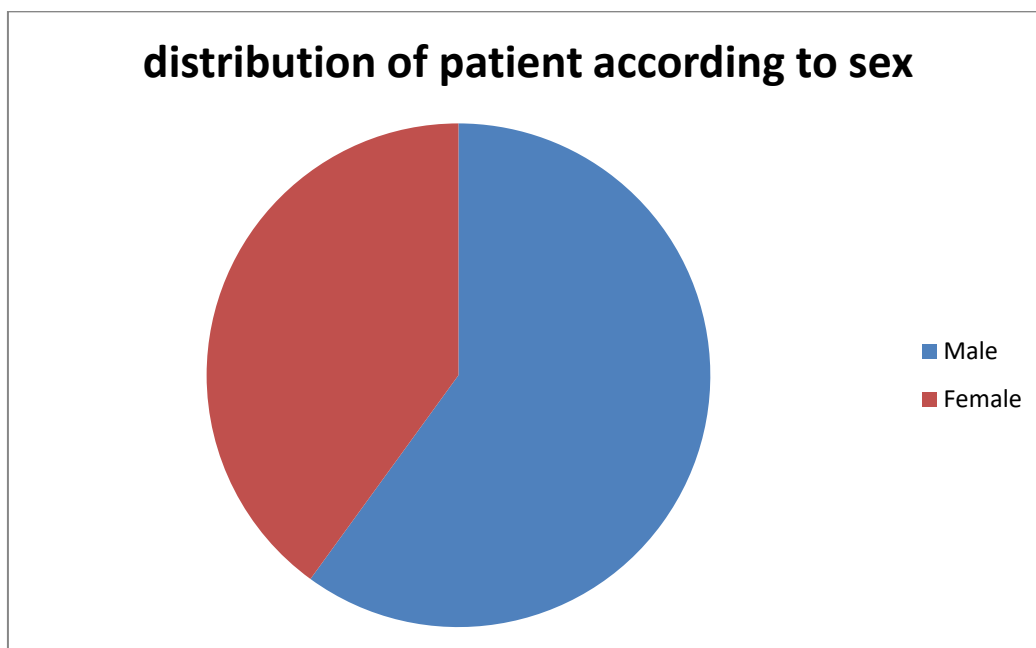
| Sex    | Number | Percentage |
|--------|--------|------------|
| Male   | 9      | 60         |
| Female | 6      | 40         |
| Total  | 15     | 100        |

**Table 3.** Distribution of patients according to age and sex.

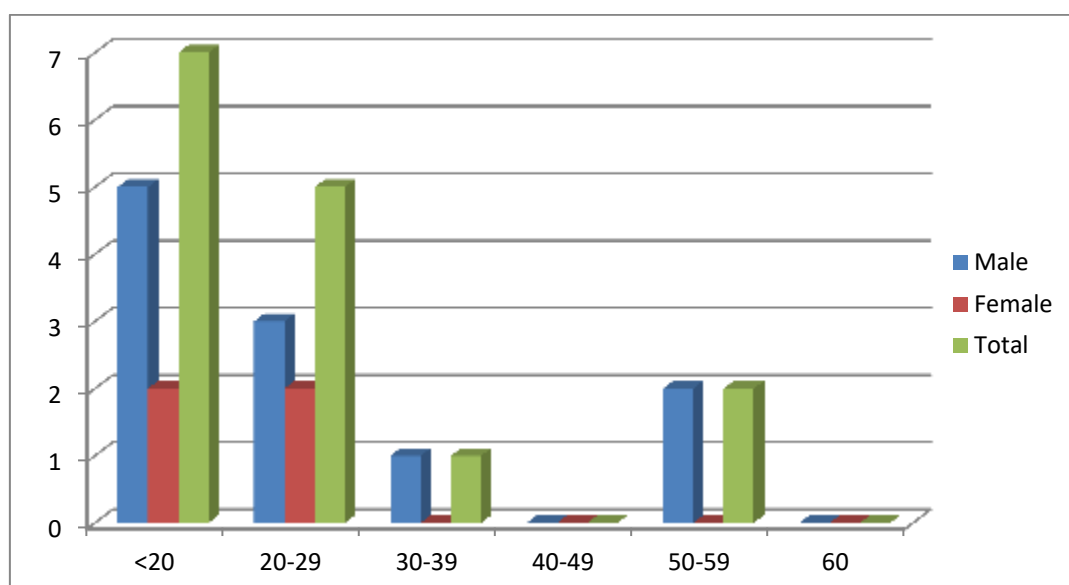
| Age   | Males |       | Females |      | Total |       |
|-------|-------|-------|---------|------|-------|-------|
|       | No.   | %     | No.     | %    | No.   | %     |
| <20   | 5     | 45.45 | 2       | 50   | 7     | 46.66 |
| 20-29 | 3     | 27.27 | 2       | 50   | 5     | 33.33 |
| 30-39 | 1     | 9.09  | 0       | 0    | 1     | 6.66  |
| 40-49 | 0     | 0     | 0       | 0    | 0     | 0     |
| 50-59 | 2     | 18.18 | 0       | 0    | 2     | 13.33 |
| 60    | 0     | 0     | 0       | 0    | 0     | 0     |
| Total | 11    | 100%  | 4       | 100% | 15    | 100%  |

## 4)Figures:

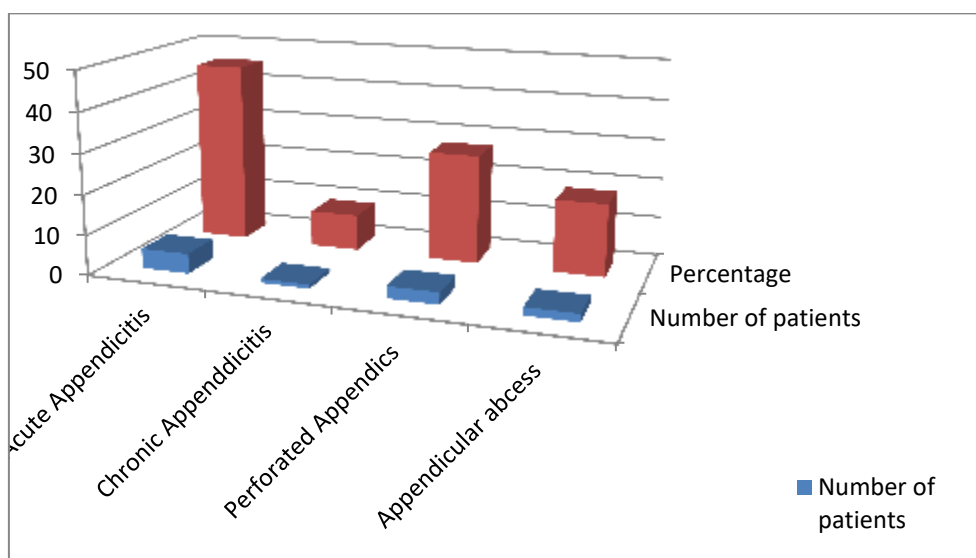
**Figure 1.** Distribution of patients according to CT findings



**Figure 2.** distribution of patient according to sex



**Figure 3.** Distribution of patients according to age for males and females.



**Figure 4.** Distribution of patients according to type Appendicitis or its complication.

### DISCUSSION

Appendicitis is an inflammation of the vermiform appendix, that typically result in abdominal tenderness, anorexia, and abdominal pain.

Computed Tomography is a highly effective and accurate cross sectional imaging technique in diagnosing and staging appendicitis. pelvi-abdominal Computed Tomography scanning with or without intravenous & oral contrast can be done, according to radiologist preference. However targeted Computed Tomography technique in appendix evaluation is done in cases that strongly suspected for appendicular pathology. Computed Tomography scanning provide direct visualization of the appendix, other intra-abdominal structures and peri appendiceal region.

Gangrenous appendicitis shows intraluminal loculated air and Enlargement of the appendix with associated fluid.

Perforated appendicitis is mostly accompanied by abscess formation or pericecal phlegmon. Other findings include marked ileocecal thickening, extraluminal air, small-bowel obstruction, peritonitis and localized lymphadenopathy [6].

Visualization of the appendiceal wall clearly is very important in order to differentiate Appendicitis from various

abdominal appendicitis mimics for accurate diagnosis of Appendicitis. so, the i.v. contrast enhancement is superiorly applied more than that without enhancement. Administration of colonic or oral contrast material is also recommended for improving diagnostic accuracy, these procedures are difficult to be implemented, especially in the emergency cases. For these reasons, we usually prefer the i.v. contrast enhancement in diagnosing acute abdominal diseases, including Appendicitis, especially in the emergency cases.

In the present study, we concentrate on continuity and thickness of the appendiceal wall, that is very simple and easy in assessment by physicians especially in emergency cases. The normal appendix thickness is less than 1 mm. When appendix got inflamed, it usually appears thickened, asymmetric and enhancing with i.v. contrast from 1 to 3 mm thickness. Therefore, we focused on the continuity and thickness of the appendiceal wall as key factors in CT grading.

In the present study, minimum thickness of the MDCT slices causes variation in the pathologic outcomes in some cases. In cases such as gangrenous status, the ability of visualization of the appendix is affected by surrounding organs caused by appendiceal inflammation in surrounding areas, inducing



radiological artifacts on CT. these artifacts causes difficulty to distinguish between stages of Appendicitis, especially advanced stages. Introduction of multiplanar reconstruction with additional lateral and coronal reformation using MDCT in order to reduce the effects of this variation on the pathological outcomes may be necessary. Coronal and axial reformation of MDCT have equal specificity and sensitivity for the diagnosis of Appendicitis.

However, additional MDCT coronal reformation improves the physician confidence in diagnosing appendicitis.

Multiplanar reconstruction of sagittal and coronal images provides rapidly more objective representation of the position and shape of appendicitis especially in the emergency department [7]

### CONCLUSION

MSCT signs of appendicitis include increase in appendix thickness more than 6 mm in diameter, inability of the appendix filling with oral contrast medium or air up to its tip, and wall enhancement with intravenous contrast medium.

Presence of an appendicolith, surrounding inflammatory changes and cecal apical changes are helpful signs in diagnosing acute appendicitis.

MSCT also is useful in diagnosing complications of appendicitis e.g. appendiceal perforation, phlegmon or an abscess formation, hepatic abscess, and Pyelophlebitis.

To conclude MSCT is helpful for accurate and prompt diagnosis in suspected cases of appendicitis & its complications and conditions that mimic appendicitis.

### Declaration of interest

The authors report no conflicts of interest. The authors alone are responsible for the content and writing of the paper.

**Funding information:** None declared

### REFERENCES

1. Gaetke-Udager K, Maturen KE and Hammer SG: Beyond acute appendicitis: imaging and pathologic spectrum of appendiceal pathology. *EmergRadiol* 2014 21:535–542
2. Naeger, Chang D, P Kolli P, Shah V, W Huang W and Theoni RF: Neutral vs positive oral contrast in diagnosing acute appendicitis with contrast-enhanced CT: sensitivity, specificity, reader confidence and interpretation time. *The British Journal of Radiology* 2011, 84, 418–426
3. Apisarnthanarak P, Suvannarerg V, Pattaranutaporn P, Charoensak A, Steven S. Raman SS and Apisarnthanarak A: Alvarado score: can it reduce unnecessary computed tomographic scans for evaluation of acute appendicitis. *American Journal of Emergency Medicine* 2014
4. Kaddah R and Ayad A: Multidetector CT evaluation of alternative diagnosis of clinically suspected acute appendicitis, appendicular and nonappendicular lesions. *The Egyptian Journal of Radiology and Nuclear Medicine* 2016, 47, 669–677
5. Lin W and Lin H: Multidetector computed tomography in the evaluation of pediatric acute abdominal pain in the emergency department. *BioMedicine (ISSN 2211-8039)* June 2016, Vol. 6, No. 2, Article 4, Pages 20-24
6. Govindarajan A, Dev B, Santosham R and Joseph S: Computed tomography diagnosis of acute appendicitis—Pictorial essay. *Surgical Science*; P. 109-116.
7. Hashizume N, Iinuma Y, Hirayama Y, Nitta K, Iida H, Shiotani M, et al: Contrast-enhanced multidetector-row computed tomography can predict pathological findings of acute appendicitis in children. *Acute Medicine & Surgery* 2016; 3: 21–25

**To Cite This Article:** Naglaa HS, Amr MA, Ayman AE. Role Of Computed Tomography In Diagnosis Of Appendicitis And Its Complications. *ZUMJ* 2019;25(6);840-846. DOI: 10.21608/zumj.2019.10442.11020.